

***Scalp flaps &  
Craniotomy principles***

# Scalp flaps-

## Historical perspective

- Neolithic period in 2000 B.C
- 19<sup>th</sup> century- trephines
- 1889 Wagner first osteoplastic bone flap
- Gigli saw for craniotomy- Obalinski in 1897
- Electric and gas powered high speed drills

# Anatomic and neurovascular considerations

- 5 layers of scalp:
  - S**kin
  - C**onnective tissue
  - A**poneurosis
  - L**oose areolar tissue
  - P**ericranium

# Land marks

- Nasion
- Bregma
- Lambda
- Inion
- Pterion:  
Middle meningeal  
artery
- Asterion:  
Transverse sigmoid  
junction

- Fronto- temporal branch:
  - anterior branch
  - middle branch
  - posterior branch
- Middle division: 1 cm anterior to superficial temporal artery, subgaleal pad of fat

*Dissect between superficial and deep layers of superficial temporalis fascia*

# Blood supply

- Superficial temporal artery
- Occipital artery
- Posterior auricular artery
- Supra orbital and trochlear vessels

# Principles of craniotomy

- Preoperative review of patient
- Preparation of scalp
- Positioning of patient on the table
- Scalp toilet
- Marking of the incision
- Draping

# Planning

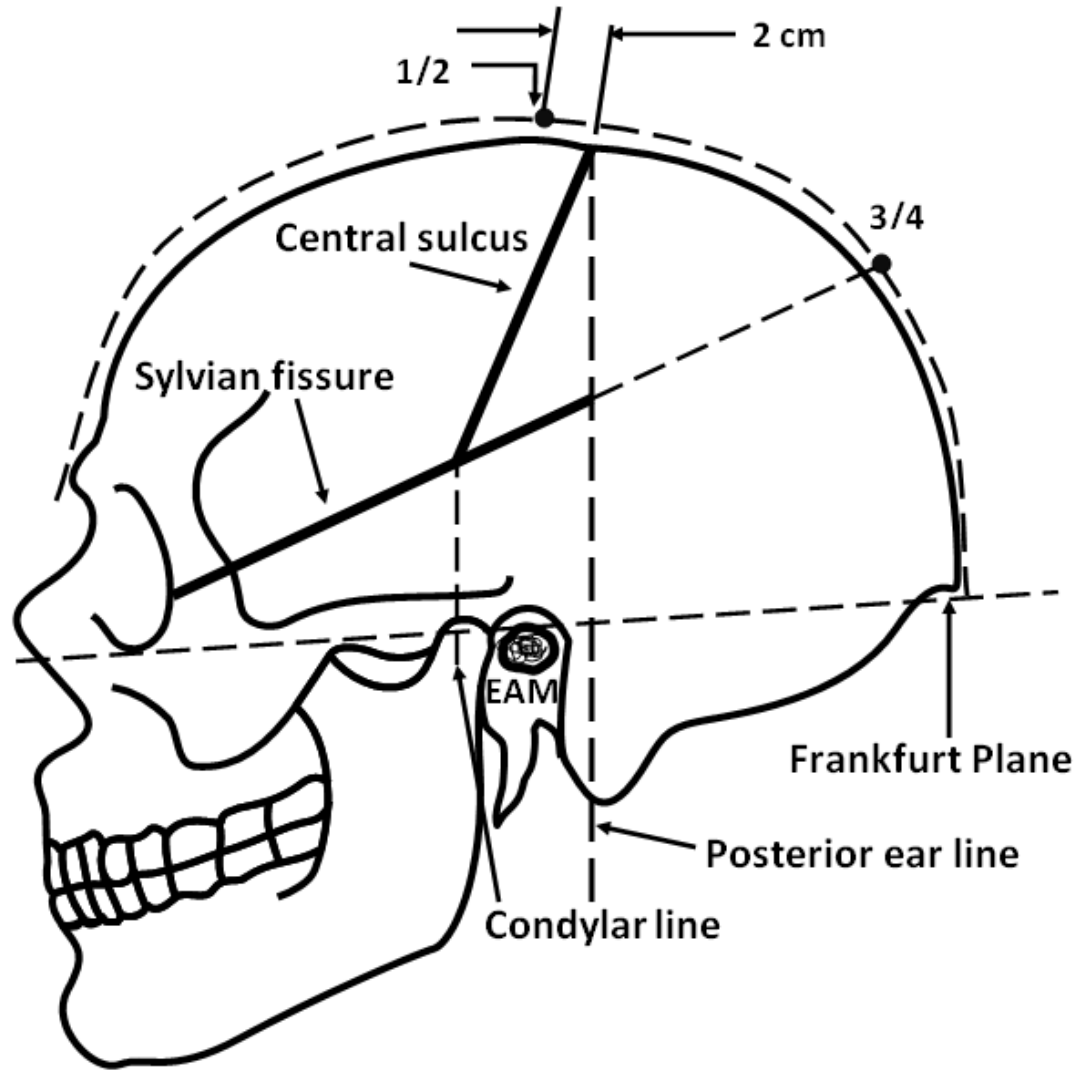
- Position of lesion
- Position of important structures
- Contingency plan for enlarging incision
- Obtain adequate closure



# Principles

- General principles:
  - Surgical exposure of the lesion
  - Neuro vascular supply
  - Cosmetic effect
- Types:
  - Random pattern
  - Based on named vessel
- Length not  $> 1.5$  times base
- Integrity of major vascular flap to be maintained
- Incision in hair containing region
- No crossed incisions

# Taylor Haughton Lines



# Principles

- Skin incised with galea
- Pressure over the scalp
- Periosteum raised with scalp or separately
- Raney's clips, bipolar, Haemostatic artery forceps
- Adequate retraction
- Inner surface protected with moistened gauze
- Roller gauze
- Dissect in interfascial fat which is encountered within 4 cm of orbital rim

# Types of craniotomies

- Flap craniotomy
- Trephine craniotomy
- Flap craniotomy:
  - Osteoplastic
  - Free bone flap

# Bone flaps

- Most direct access to target
- For cerebral convexity directly centered over the lesion
- Number of burr holes varies
- Separation of underlying dura
- Beveling effect

# Bone flaps

- If dura is lacerated during cutting, saw should be turned off and removed backwards via entrance hole
- Air cells opened:
  - Remove the mucosa
  - Pack with betadine soaked gelfoam
  - Pack with bone wax
  - Cover it up with vascularized tissue

- Proposed bony cuts over venous sinuses should be done last-vascularity adherence
- Cut sinus can be sewn/ tamponade
- Bony bleeds stopped with bone wax
- Penfield's dissector to separate dura
- Epidural tacking sutures to control epidural bleeding before opening dura
- Others don't in order to protect cortical blood vessels
- Tailor to avoid dural venous channels

# Opening of Dura mater

- Manually palpate the dura
- Dura opened as straight, curved or flap like incisions
- Flaps based towards sinuses
- Opened with sharp hook and knife
- Incision further opened with dural scissors
- Placement of cottonoid along the intended incision
- Suitable cuff of dura around the bone for suturing later



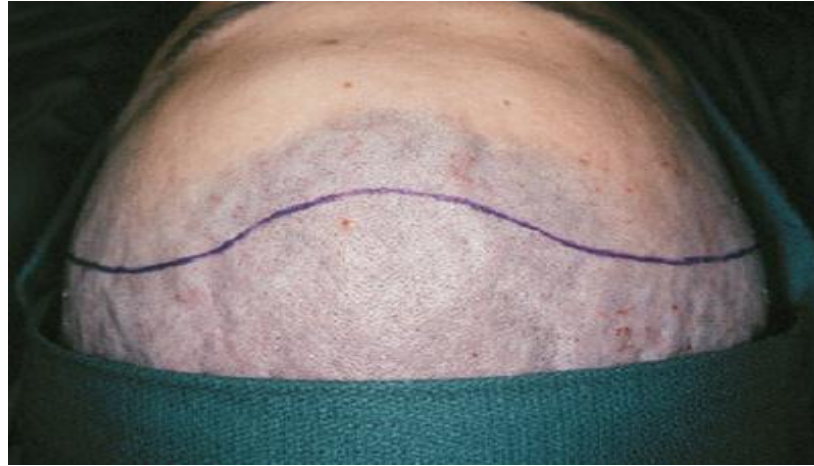# Closure

- Closure in layers
- Check for BP- valsalva maneuver
- Hitch suture
- Water tight but not tension
- Bone flap replacement
- Skin closed in two layers

# Bicoronal/ Souttar flap

- Large exposures of anterior cranial fossa and sella
- Fronto-temporal lesions and cranial base
- Superior to zygomatic arch, 1 cm anterior to tragus- extends over the bregma to the corresponding site on the opposite side
- Reflect up to orbit rim
- Supraorbital/ trochlear vessels

# Bicoronal/ Souttar flaps



# Frontal/ Bifrontal bone flaps

- Suitable for frontal lobe, sub-frontal approaches to anterior skull base, and trans cortical access to ventricles

# Frontal/ Bifrontal bone flaps

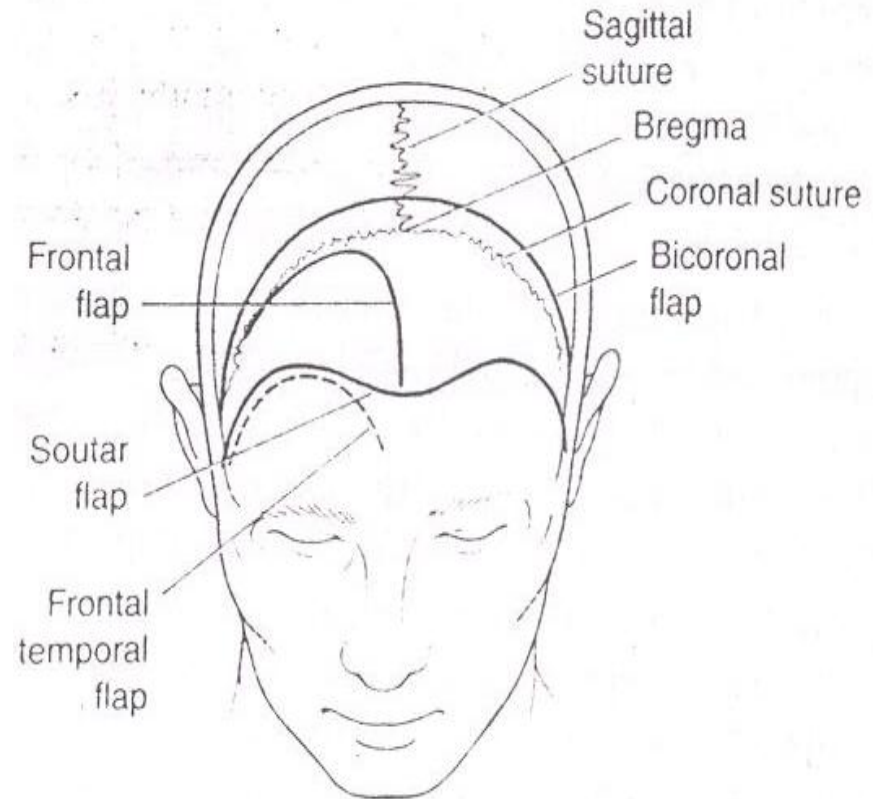
- An extended frontal or bi-frontal craniotomies for exposure of sella, anterior cranial base
- Supine with head extended for these
- Holes placed on either sides of sagittal sinus and intervening bone is removed with rongeurs or drill
- Either removed as single piece or conversion of frontal flap to bi-frontal flap
- Combining a frontal flap with pterional flap

# Frontal/ Bifrontal bone flaps

- Goals of surgery dictate the craniotomy
- Bilateral orbital craniotomies may be added to minimize frontal lobe retraction
- Dural openings for a unilateral frontal craniotomy usually consist of flap reflected towards sagittal sinus
- Superior sagittal sinus may have to be ligated

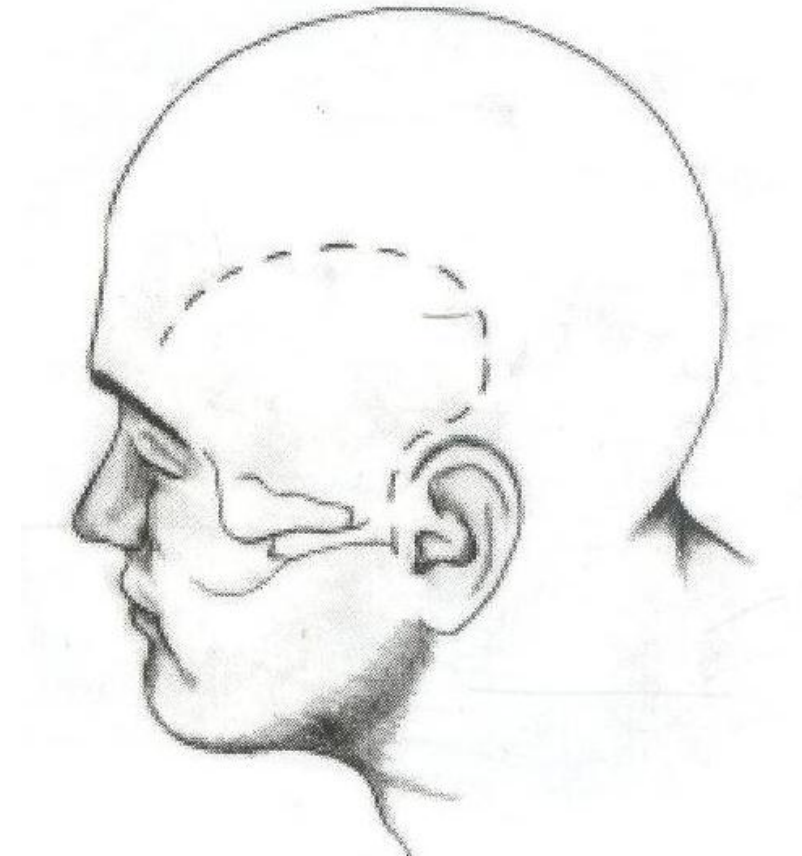
# Frontal flap

- Exposes anterior frontal lobe
- Begins along coronal suture and curves anteriorly along the midline preferably ending at hair line



# Temporal flap

- Anterior temporal lobe and subtemporal access
- Based on zygoma
- Goes behind the ear
- Extends anteriorly just behind the superior temporal line to the hair line





- Link to video –
- <http://www.aiimsnets.org/NeurosurgeryAnimationVideoTemporalCraniotomy.html>

# Fronto- temporal (pterional) bone flap

- Popularized by Yasargil
- Most useful for aneurysms of anterior circulation, basilar top, also tumors of retro orbital, parasellar and subfrontal areas
- Supine position with head end elevated to 30 degrees and rotated by the same to opposite side

# Fronto- temporal (pterional) bone flap

Link to video -

<http://www.aiimsnets.org/NeurosurgeryAnimationVideoPterionalCraniotomy.html>

# Fronto-temporal flap

- Used for most pterional craniotomies
- Combines frontal and temporal skin flaps
- Extends from zygoma to 1-2 cm off the frontal midline following a curve behind the natural hair line
- Temporalis muscle either dissected or reflected as a separate layer
- In the later instance a cuff is left superiorly so as to suture it

# Fronto- temporal (pterional) bone flap

- Temporalis muscle dissected or reflected
- Bone flap centered over the pterion
- Key burr hole, frontal burr hole, posterior burr hole, last burr hole just above the zygoma
- Further bone may be removed from the inferior temporal squama
- To improve vision, drill the sphenoid ridge
- Dural flap based on the orbit

# FTOZ

- Addition of orbito-zygomatic craniotomy will allow for a more lower and anterior approach
- Suited for para-sellar, inter-peduncular lesions,
- Basilar top aneurysm,
- Carotico-ophthalmic aneurysms.

# FTOZ

Link to video -

<http://www.aiimsnets.org/NeurosurgeryAnimationVideoFrontotemporalOrbitozygomaticFTOZApproach.html>

# Question mark skin flap

- Cranial trauma
- Exposure to whole hemisphere
- Based on zygoma
- Blood supply from superior temporal and supra orbital vessels
- Curves around 3.5 cm posterior to external auditory meatus
- Anterior limb extends to hair line



# Horse shoe skin flap

- Expose any portion of cerebral convexity
- Inverted “U” shaped with base directed towards vascular supply
- Subtemporal exposure:  
anterior limb 1 cm  
anterior to the tragus
- For anterior transcallosal approaches: over coronal suture

# Mitre skin flap

- Mitre hats worn by bishops
- Occipital lobe, posterior falx and superior tentorial surface
- Inion to vertex: vertical limb
- Upper limb then falls over posterior parietal region towards the ear
- Blood supply from the occipital artery

# Linear and curvilinear incisions

- Limited exposures
- Simplicity
- E.g.: MLSOC

RMSOC

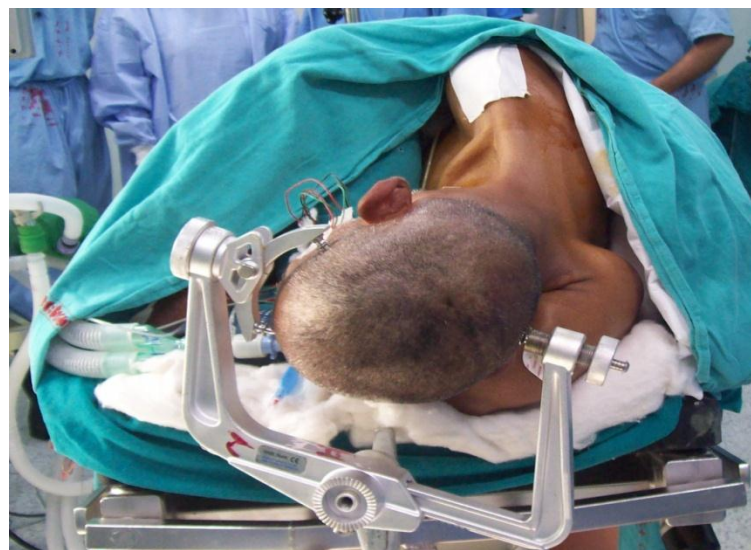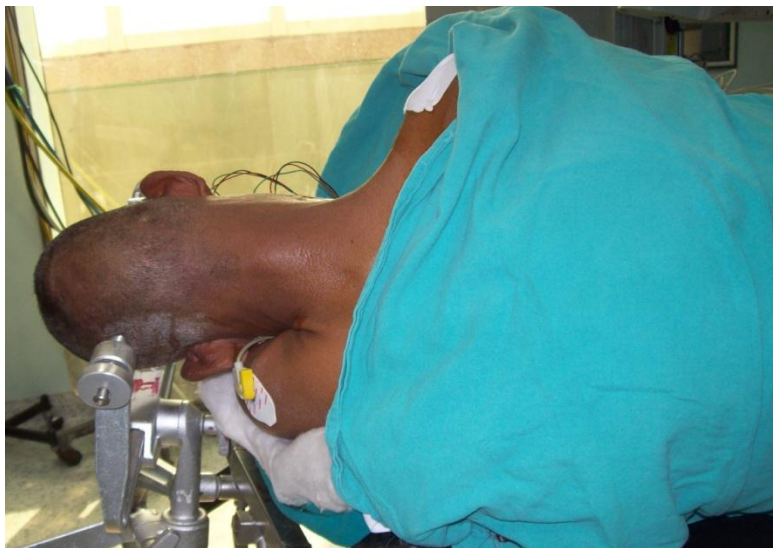Hockey stick incisions

Linear incisions for temporal lobe  
& subtemporal access

# CP angle tumors

- Lateral
- Prone
- Three quarters prone
- Sitting

# Retromastoid suboccipital transmeatal approach



# Retromastoid suboccipital transmeatal approach

Link to video -

<http://www.aiimsnets.org/NeurosurgeryAnimationVideoRetromastoidSuboccipitalCraniotomy.html>

- Incision –
  - Vertical linear ( 1 cm medial to the mastoid process )
  - ‘S’ / Lazy ‘S’
  - Inverted ‘J’ -shaped/ Hockey-stick
- Anatomical variants-
  - Dolichoectatic VA/Occipital artery
  - Hypoplastic VA (20 %)- Avoid extreme flexion

# MLSOC

Link to video -

<http://www.aiimsnets.org/NeurosurgeryAnimationVideoMidlineSuboccipitalCraniotomy.html>

# Poppens-Suboccipital Transtentorial Approach

Link to video -

<http://www.aiimsnets.org/NeurosurgeryAnimationVideoPoppensSuboccipitalTranstentorialApproach.html>



***Thank you***

